

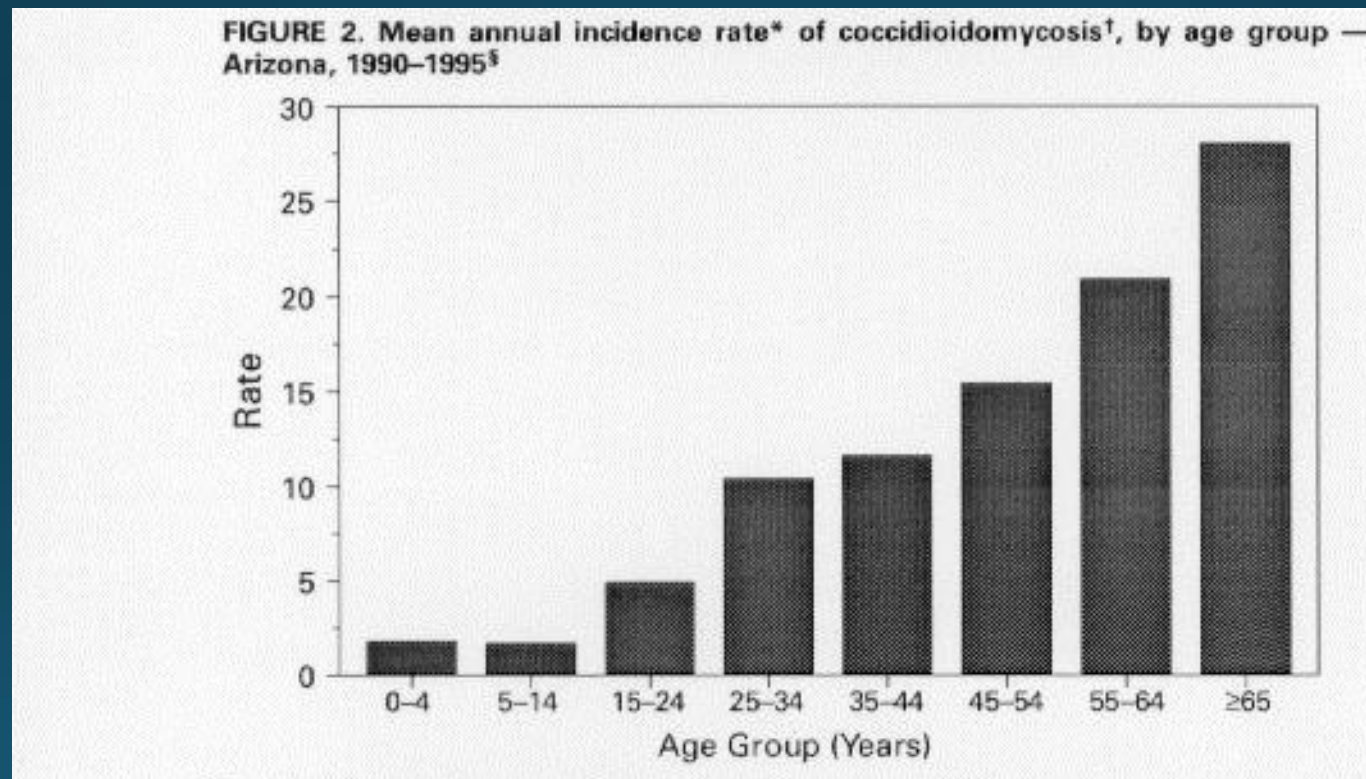
Ziad M Shehab MD
The University of Arizona

Valley Fever in Children

Challenges in diagnosing Valley Fever in children

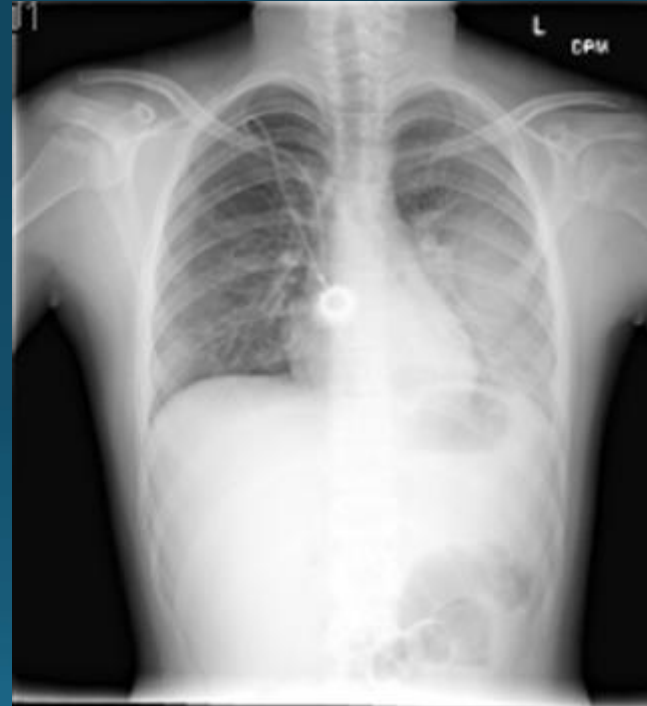- Most infections are not clinically apparent
- Competes for attention with many other respiratory infections
- Diagnosis generally requires a blood test
- Blood test is not very sensitive
- Limited ability to give a history
- Wide variety of presentations

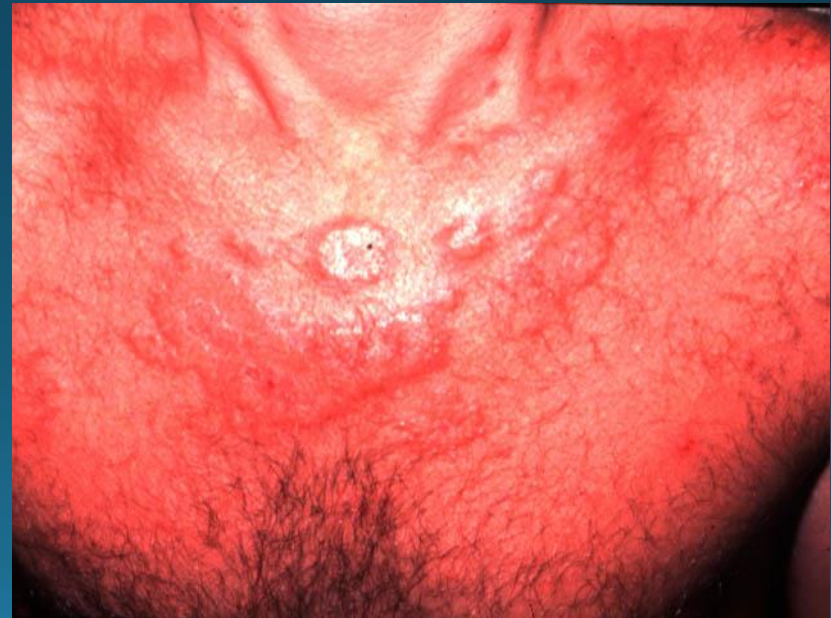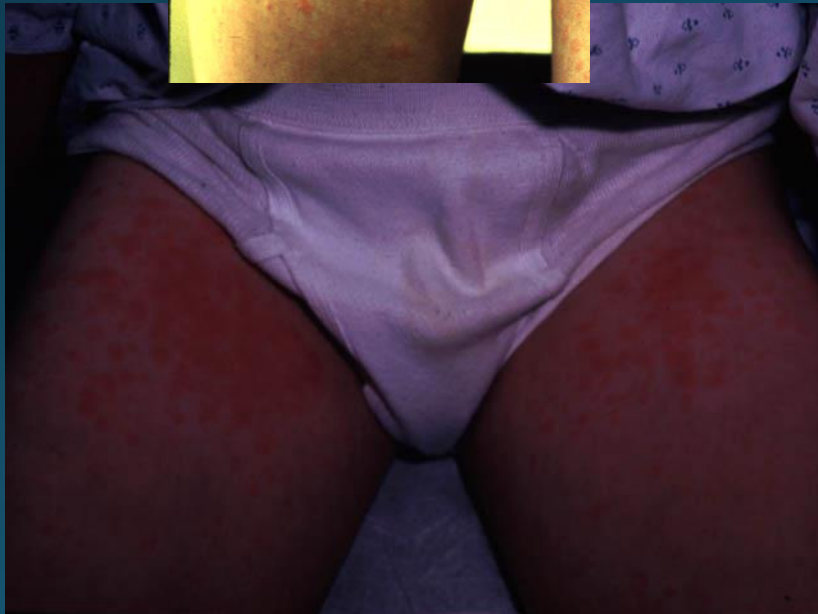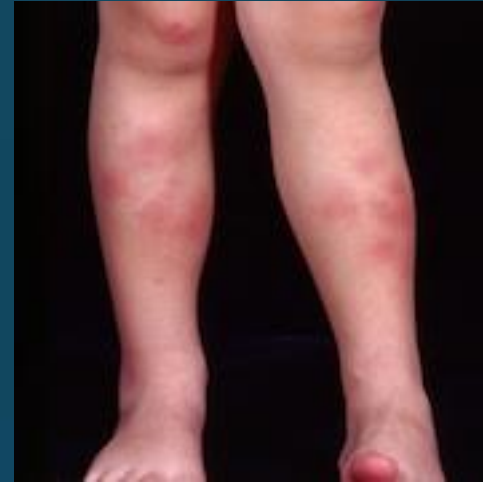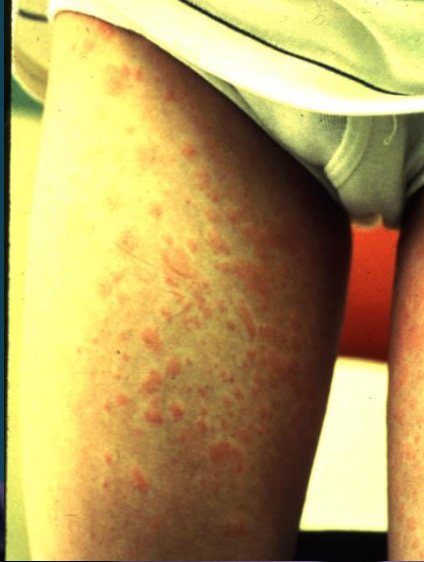Cocci: Annual incidence by age, Arizona 1990-5



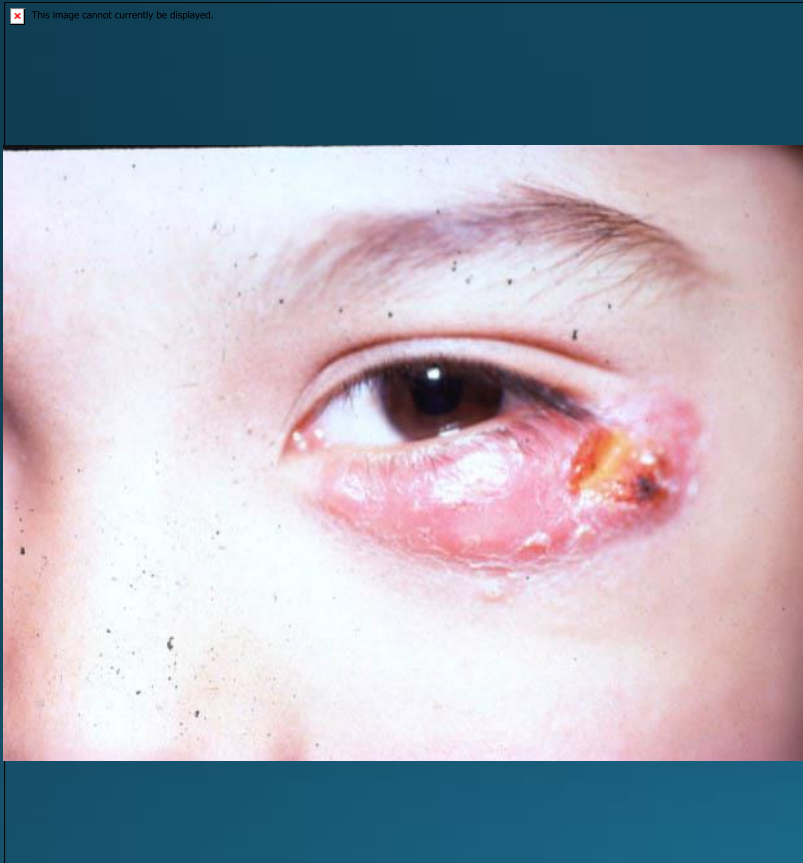
12 yo girl

- Dry cough for 2 weeks with lower left chest pain
- Discharged 5 days later on antibiotics
- 3 days later develops fever
- No respiratory distress
- Cocci blood tests repeatedly negative
- Bronchoalveolar lavage positive for *Coccidioides immitis*



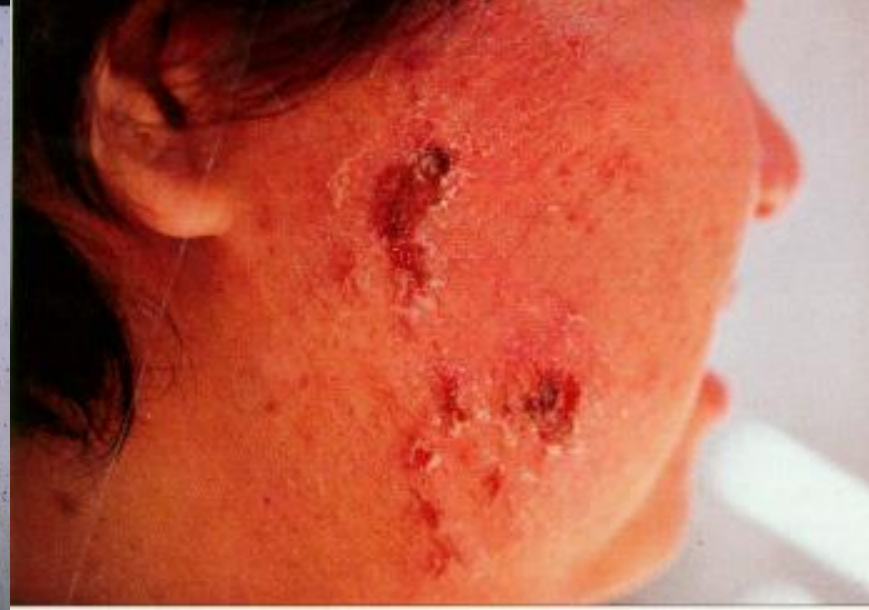
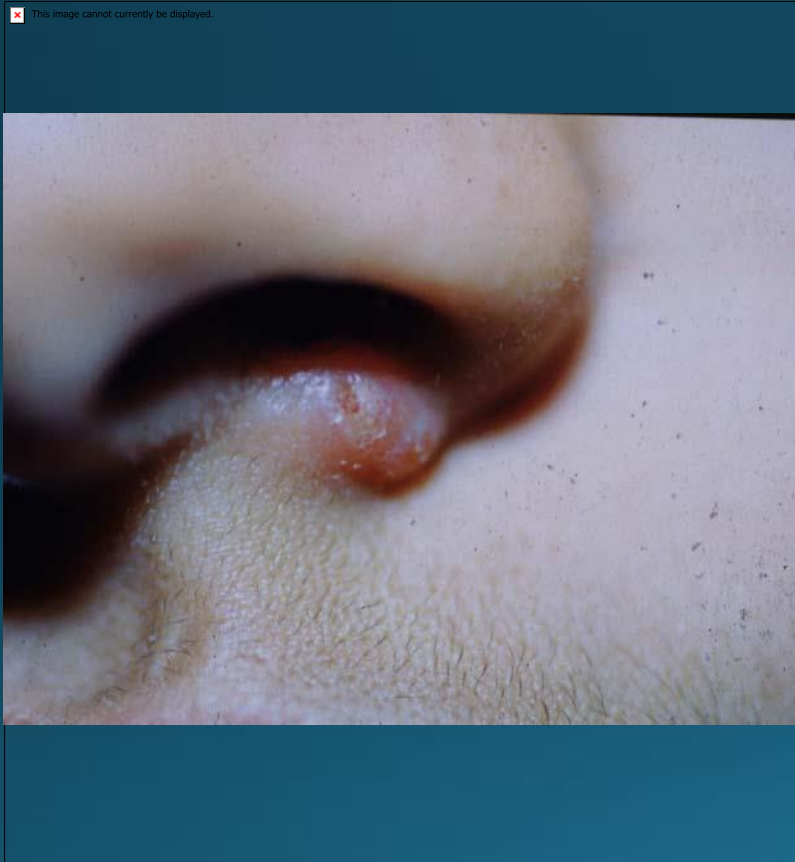
Primary cutaneous cocci



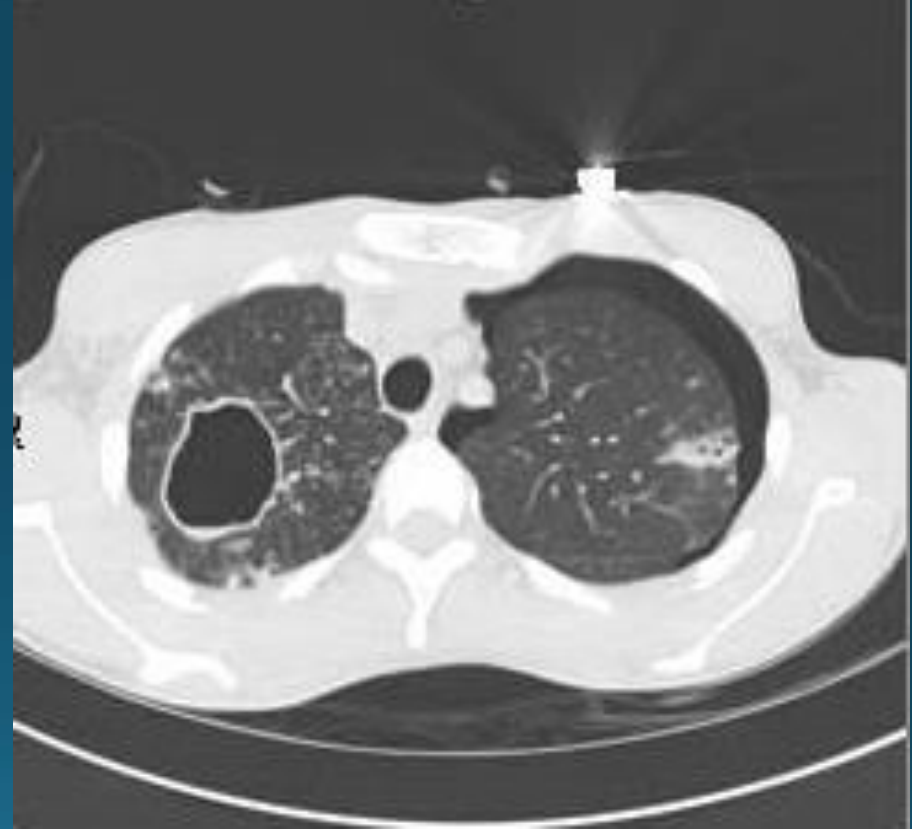- Rare
- Result from direct inoculation
- Serology usually remains negative
- Occurs within 1-2 weeks of injury in absence of respiratory disease

Cutaneous cocci: Disseminated



Chest pain for 2 months

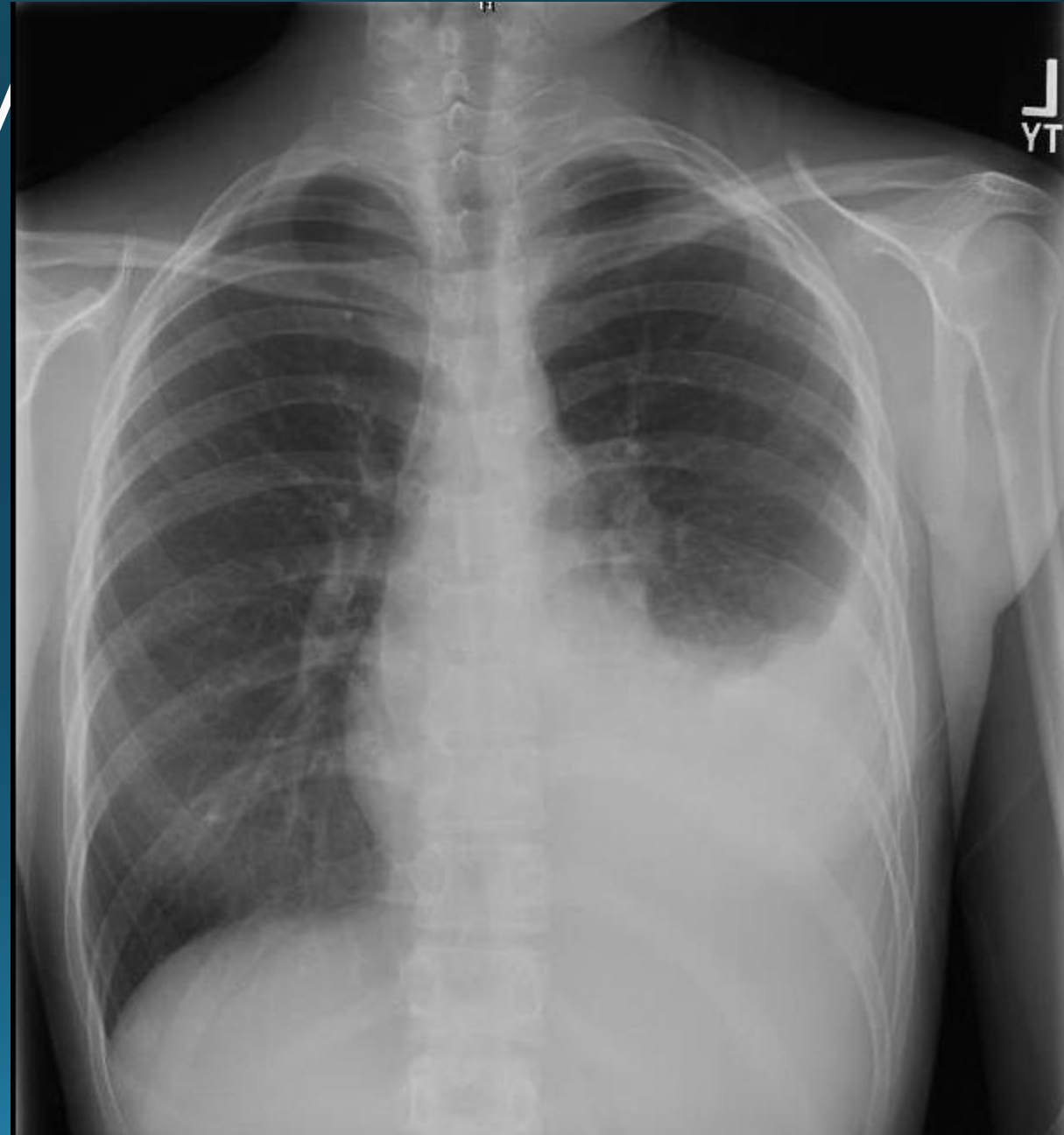
- 18 yo with 2 month history of left chest pain
- Sudden onset sharp, stabbing left sided chest pain radiating to arm
- Green sputum production
- No shortness of breath, cough or fever



12 yo cough x 4 days

- Dry cough for 4 days
- No chest pain
- No shortness of breath
- Mild decrease in exercise tolerance
- No fever

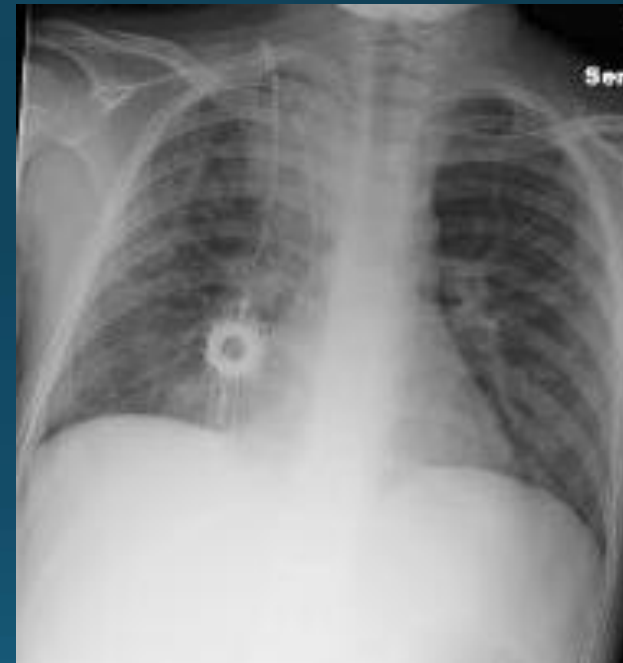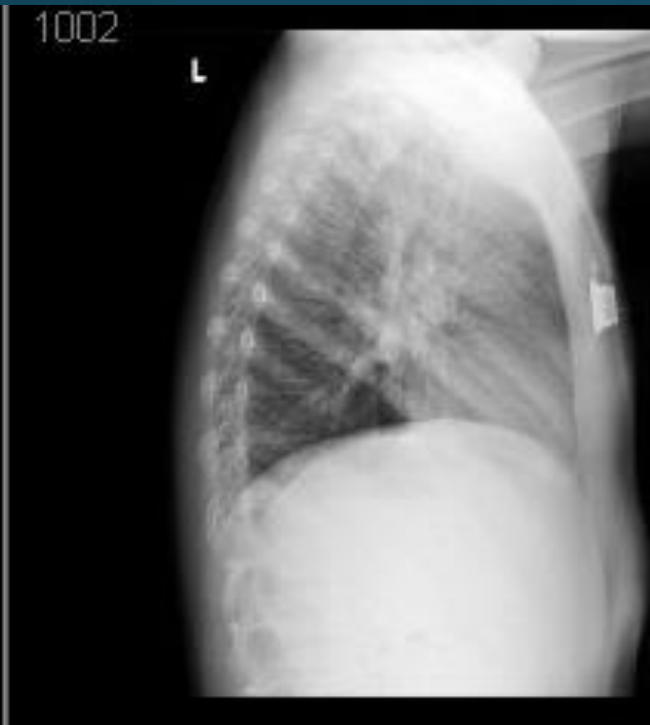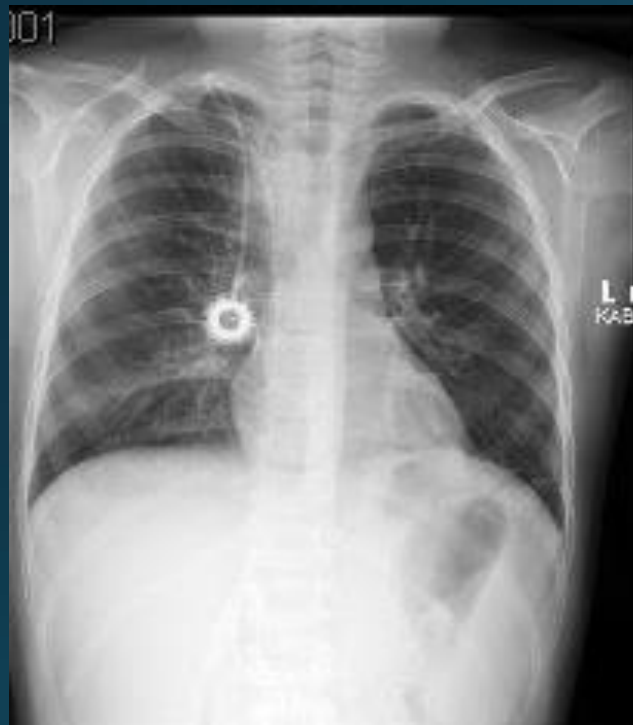- Resolved with medical therapy



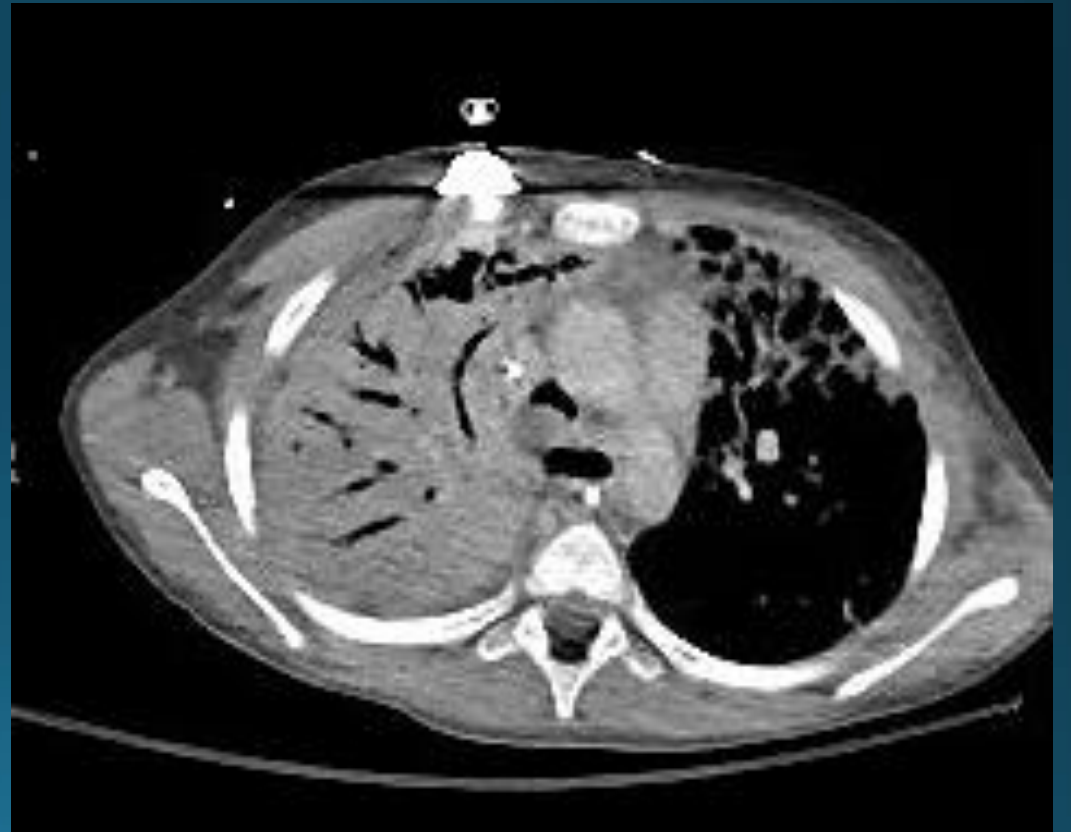
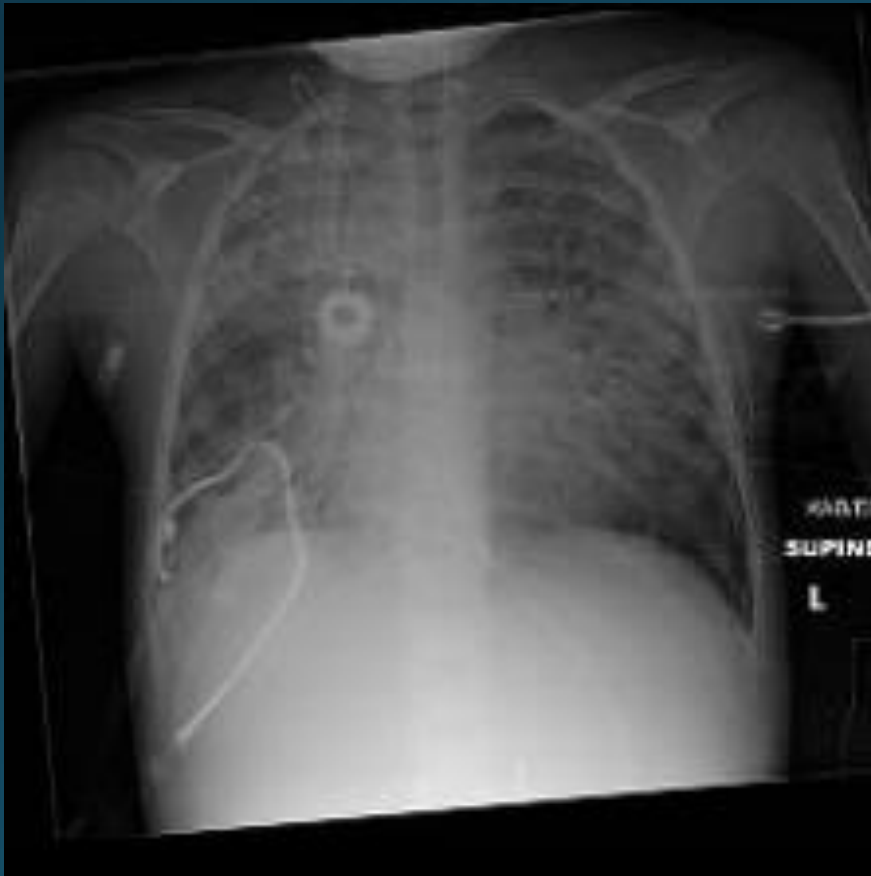7 yo boy with leukemia

- In remission
- Fever for one day
- Cough and nasal congestion for 3-4 months
- Yellow sputum
- Pneumonia (?viral on chest X ray)

7 yo boy with leukemia

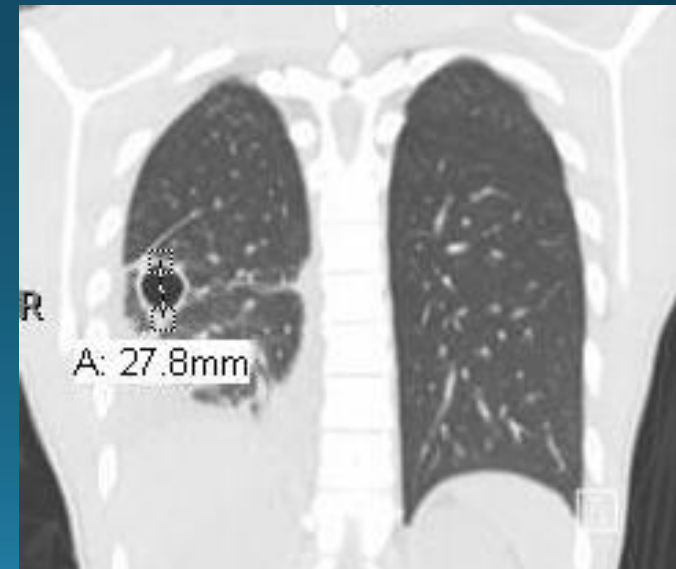
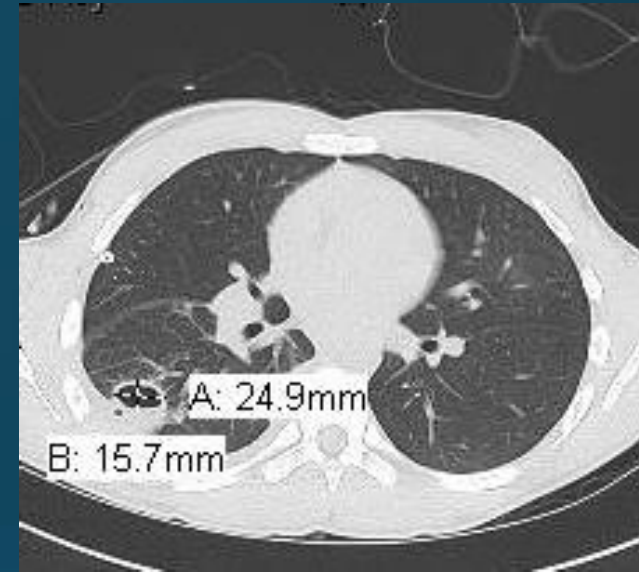


7 yo with leukemia

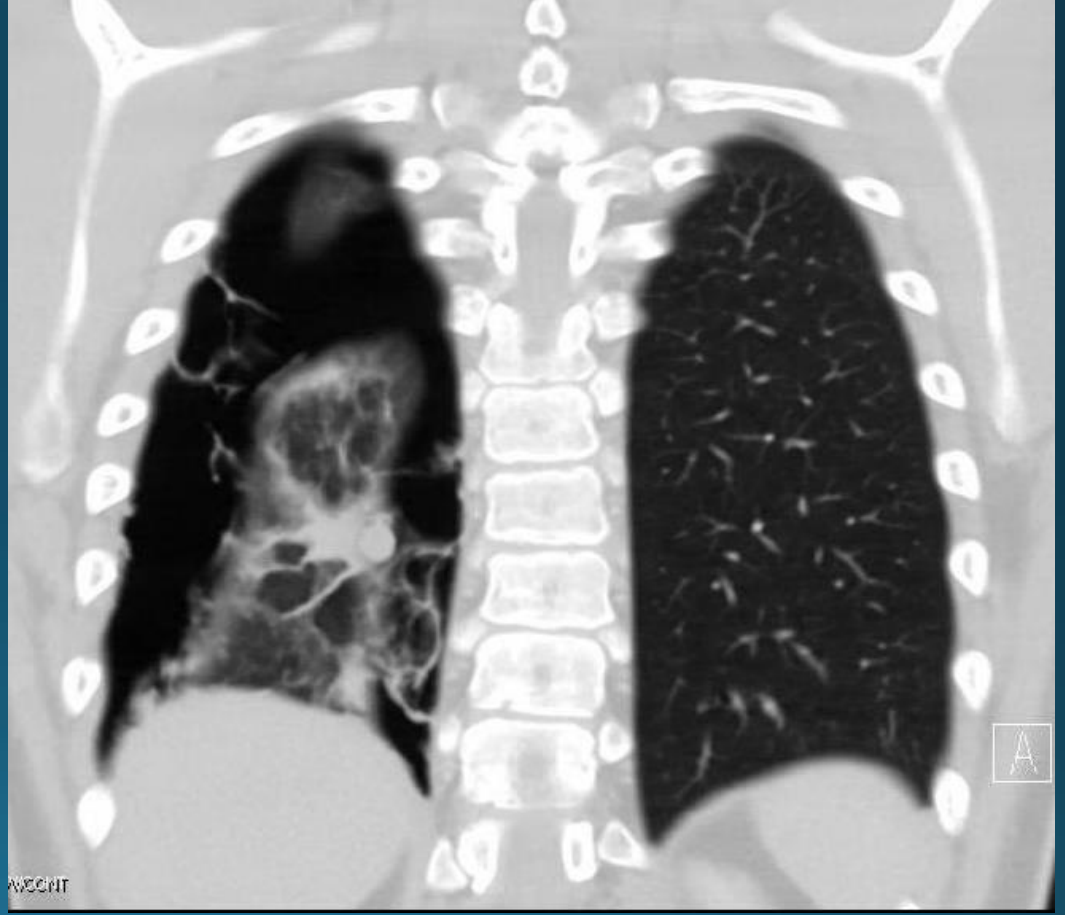
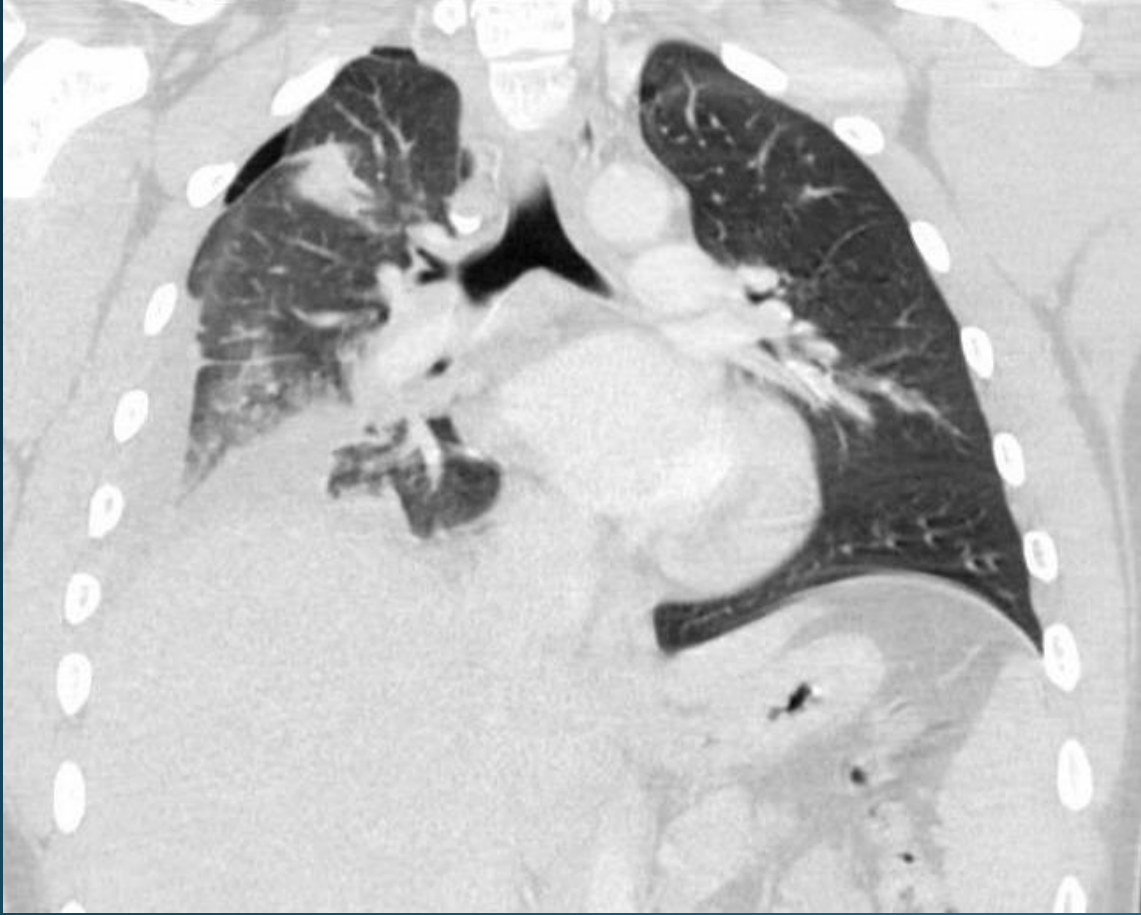
17 yo with chest pain

- 17 yo AA young man
- 4 day h/o right sided chest pain, rapid onset with dyspnea
- No fever
- Required chest tube placement to evacuate pneumothorax



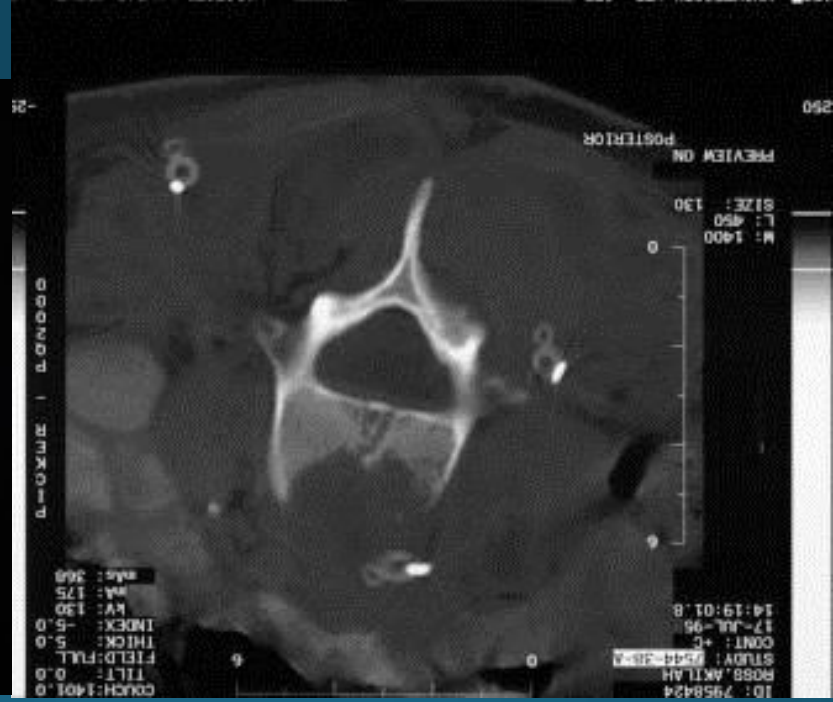
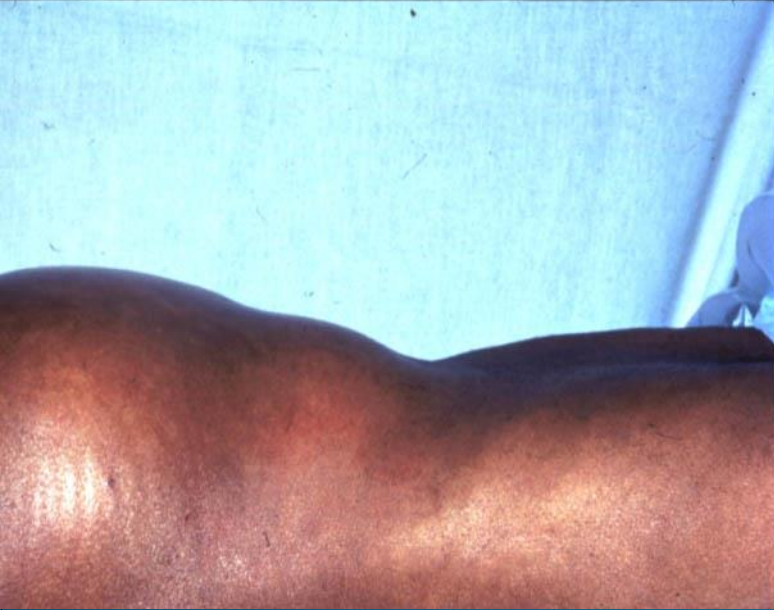12 yo with chest pain for 2 months



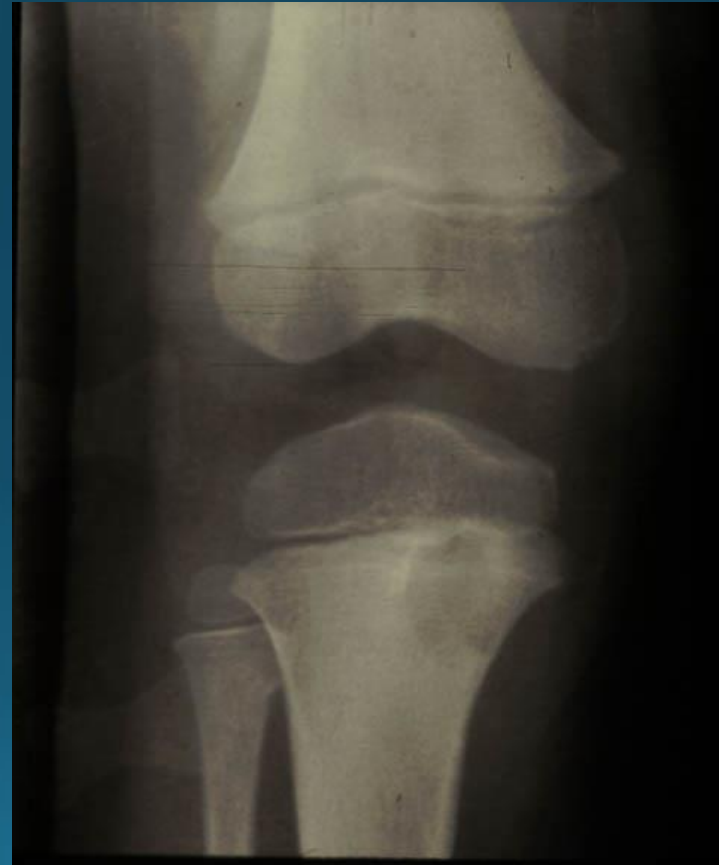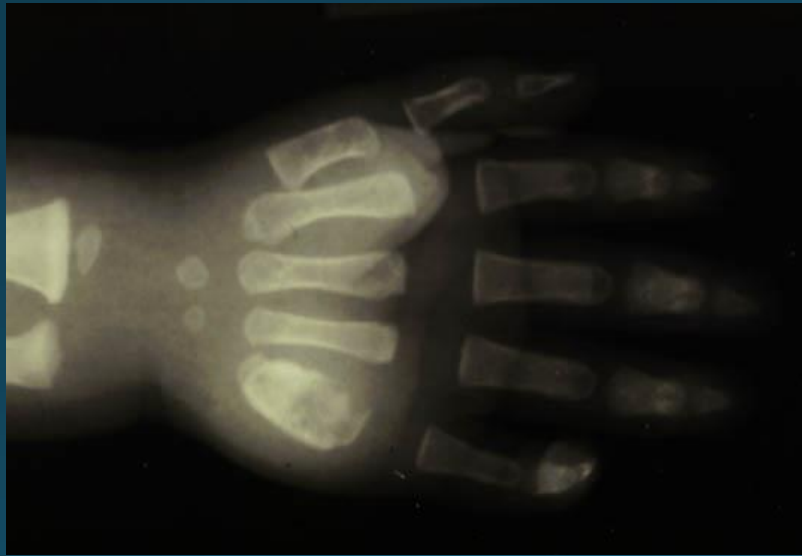Osteomyelitis

- About 40% of cases of dissemination
- Chronic pain with occasional swelling or erythema at site
- Usually irregular lytic lesion, rarely sclerotic
- Usual sites: vertebrae, tibia, metacarpals, metatarsals, skull

 This image cannot currently be displayed.

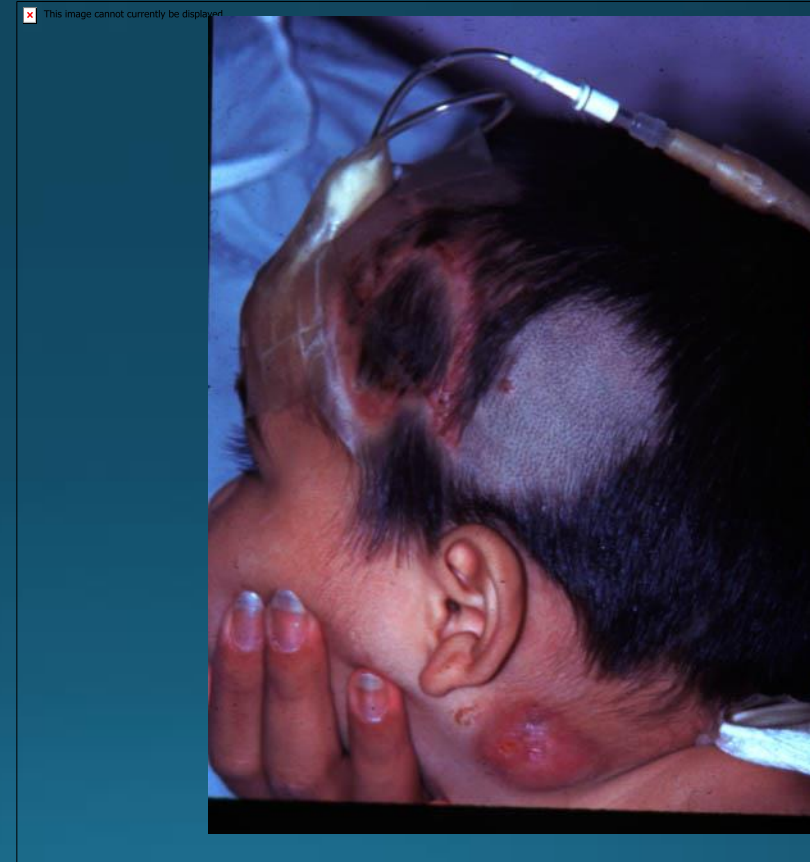

Cocci osteomyelitis



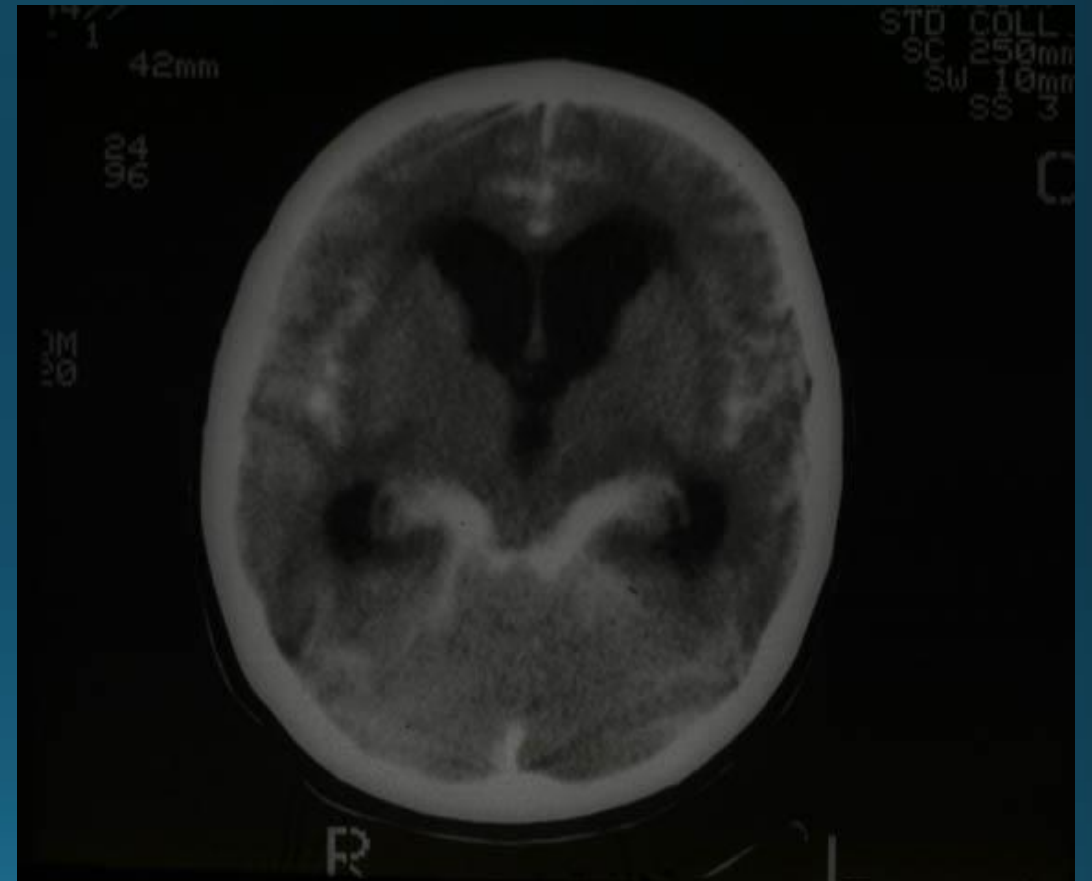Lymphadenitis

- Subacute in onset
- Often suppurative



Meningitis

- Uniformly fatal within 2 years if untreated
- Subtle, nonspecific symptoms:
 - Headache, changes in mental status, clumsiness, low grade fever, weight loss, cranial nerve dysfunction
- Often followed by hydrocephalus and signs of increased intracranial pressure
- Need to suspect and examine spinal fluid



? From cradle...

- 4 week old, 34 week gestation, twin B
- Scalp lesion, with positive culture for *C. immitis*
- Treated for 6 months with fluconazole. Mother discontinued on her own
- Baby and twin brother had positive blood tests for cocci at 4-6 weeks of age, while mom tested negative
- The baby had never left the nursery
- Returns at 21 months of age with infection of the hip, proven by biopsy to be cocci